

# Case Reports Illustrating the Application of Expert Consensus

## POPLITEAL ARTERY THROMBOSIS COMPLICATING A POPLITEAL ENTRAPMENT WITH DISTAL EMBOLIZATION

By Prof. Patrick Feugier, MD, PhD

### DIAGNOSTIC EVALUATION

A 23-year-old man without cardiovascular risk factors presented to the emergency department of our hospital with severe pain in his right foot and leg, which had been persistent for 48 hours. After a few hours of skiing, the patient abruptly felt this pain, associated with a feeling of coldness and paresthesia. This symptomatology and the disappearance of the popliteal and pedal pulses, specifically on the right side, led to the diagnosis of category IIa acute limb ischemia. CT angiography was urgently requested. It confirmed the thrombosis of the retroarticular popliteal artery, multiple thrombi in all arteries of his lower leg, the absence of parietal abnormality on the other arteries, and the presence of an arteriovenous diastasis that was caused by a complementary muscle bundle of the medial gastrocnemius muscle. The initial diagnosis of acute limb ischemia caused by a thrombosis in the popliteal artery related to a complicated popliteal entrapment was maintained (Figure 1).

### TREATMENT APPROACH

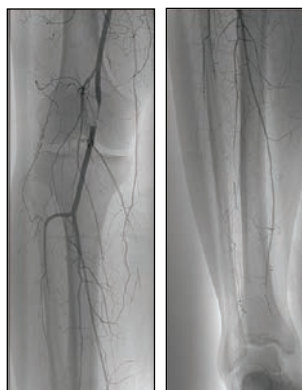

Figure 1. Angiography confirmed the popliteal thrombosis, associated with crural embolization.

A fibrinolytic procedure was proposed to the patient, who had no contraindications for this treatment. Access to the artery was conducted by an echo-guided homolateral femoral puncture. A flexible guidewire easily crossed the thrombotic lesion, and a multiperforated 4-F catheter was positioned within the thrombus. A local injection of 100,000 IU of urokinase was immediately administered. Subsequently, *in situ* fibrinolysis was

started at a dosage of 2,500 IU/kg urokinase per hour via an electric syringe pump, which was combined with systemic intravenous heparin administration (100 IU/kg/12 hours). Clinical evaluations were scheduled every hour and biological assessments every 8 hours.

At the 24-hour angiographic control, we observed an almost complete repermeabilization of the popliteal artery. The multiperforated catheter was repositioned to improve urokinase infusion into the arteries of his leg, where several residual thrombi remained. The peripheral pulses were recovered after 48 hours of thrombolysis, and control angiography confirmed complete dissolution of the intra-arterial popliteal and associated crural thrombi (Figure 2). Dynamic maneuvers confirmed the entrapment of the popliteal artery.

One week after the fibrinolytic treatment, we operated on the patient. The intervention consisted of an isolated lift of the entrapment via a posterior access. A control echo-Doppler followed by perioperative angiography confirmed the absence of residual thrombotic popliteal stenosis. Two-year follow-up showed excellent long-term results, without the need for complementary treatments.

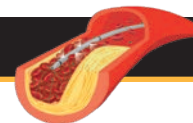
### DISCUSSION

The fibrinolytic treatment allowed us the restitutio ad integrum of arterial patency in this case of acute ischemia, without arterial surgical intervention on the lower limb arteries. The targeted intervention on the popliteal entrapment was then able to be carried out in a second procedure in excellent clinical conditions. ■

Reproduced from Della Schiava N, Feugier P. Syndrome de l'artère poplitée piégée et kyste adventiciel de l'artère poplitée. EMC - Angéiologie. 2017;12(1):1-11 [Article 19-1580]. Copyright © 2017 Elsevier Masson SAS. All rights reserved.

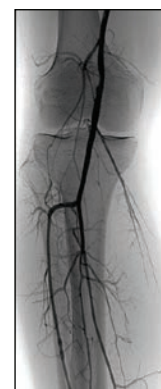

Figure 2. Control angiography after 48 hours of *in situ* fibrinolysis.



## CASE REPORT

## CATHETER-DIRECTED THROMBOLYSIS FOR ACUTE LOWER EXTREMITY BYPASS GRAFT OCCLUSION

By Prof. Romaric Loffroy, MD, PhD, FCIRSE

### DIAGNOSTIC EVALUATION

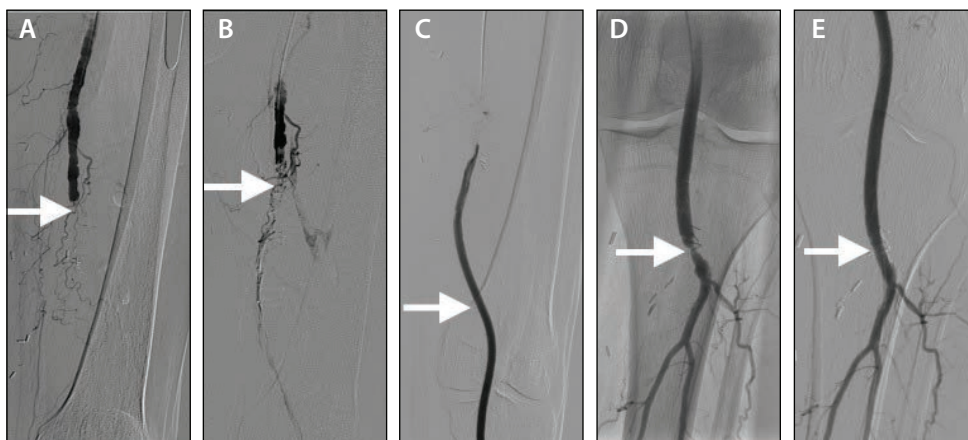
A 75-year-old man presented with acute ischemia in the left foot and calf 4 months after left popliteal artery reconstruction using a synthetic bypass graft for the treatment of a popliteal aneurysm.

### TREATMENT APPROACH

The patient was referred for catheter-directed thrombolysis (CDT) because of the risks involved in reoperation, despite warning of the bleeding risks associated with CDT therapy. Prior to the initiation of thrombolysis, coagulation tests were performed and contraindications were eliminated. Selective angiography of the left superficial femoral artery was performed through a 5-F sheath placed into the left common femoral artery via an antegrade approach under local anesthesia and ultrasound guidance. The arteriogram showed complete thrombotic occlusion of the bypass graft without any opacification of the below-the-knee arteries (Figure 1A).

A guidewire was passed through the occluded graft prior to insertion of the thrombolysis catheter. A 4-F multi-side-hole, straight catheter was then placed within the proximal part of the thrombus (Figure 1B), after which a continuous

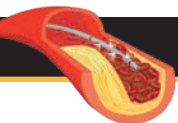
infusion of urokinase was initiated. A dose of 600,000 IU urokinase was infused in 12 hours (50,000 IU/hour). At the start of thrombolysis, 5,000 IU of unfractionated heparin was given intra-arterially. During the thrombolysis, unfractionated heparin (200 IU/hour) was administered through the introducer sheath, with the dose adjusted to activated partial thromboplastin time values to a target of two to three times the reference value. Fibrinogen, activated partial thromboplastin time, hemoglobin, platelets, and creatinine levels were checked continuously according to protocol. Follow-up angiography the next day showed no residual thrombus within the graft (Figure 1C) but did show a high-grade stenosis at the lower popliteal artery anastomosis (Figure 1D), which was successfully treated by placement of a 5- X 19-mm balloon-expandable Herculink stent (Abbott Vascular; Figure 1E). The left peroneal and posterior tibial arteries were patent at the end of the procedure, whereas the anterior tibial artery was chronically occluded. No bleeding complications occurred. No surgery or thrombectomy was needed. The patient was discharged after 2 days without any symptoms. Duplex graft surveillance was performed after thrombolysis according to local protocol. Secondary patency of the bypass graft was maintained at 3-year follow-up.



### DISCUSSION

In conclusion, intra-arterial thrombolysis using urokinase is usually a safe and effective therapy for patients with thrombotic occlusion of synthetic lower extremity bypass grafts presenting with acute limb-threatening ischemia, and it allows a high rate of secondary patency, avoiding amputation. ■

**Figure 1.** Initial arteriogram showed complete and extensive thrombosis of the left femoral bypass graft (A). A multi-side-hole catheter was placed at the proximal part of the thrombus for infusion of urokinase (B). The next day, control angiography demonstrated patency of the graft with no residual thrombus (C). Follow-up angiography also revealed a high-grade underlying stenosis at the lower popliteal artery anastomosis (D). Final angiography after placement of a balloon-expandable stent showed successful recalibration of the arterial anastomosis (E).



## TWO-STEP APPROACH FOR A THROMBOSED POPLITEAL ANEURYSM

By Prof. Jean Picquet, MD, PhD

### DIAGNOSTIC EVALUATION

An 85-year-old man without any relevant medical history presented to our hospital with sudden, persistent right lower limb pain. On physical examination, the right foot was cold and livid, without a sensory-motor deficit of the right leg. The patient's heart rate was regular, both the femoral and the left popliteal pulses were found, and filling of both popliteal regions was present. Rutherford category IIa acute right lower limb ischemia was diagnosed. A CT scan with contrast was performed, demonstrating a thrombosed popliteal artery aneurysm in the right leg and another large popliteal artery aneurysm in the left leg.

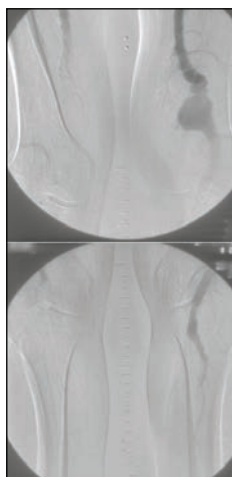


Figure 1. Initial angiography demonstrated a large left popliteal aneurysm and thrombosed arteries distal to the right superficial femoral artery.

### TREATMENT APPROACH

After diagnosis, intravenous heparin (200 IU/kg/24 hours) was infused. The patient was subsequently transferred to a hybrid operating room, where initial angiography confirmed the thrombosed aneurysm without patent distal runoff in the right leg (Figure 1). Local *in situ* thrombolysis was started prior to the surgical procedure in order to revascularize the arterial runoff vessels distal to the aneurysm. Urokinase was administered at 2,500 IU/kg per hour via a multiperforated catheter inserted using contralateral femoral access, with the multiperforated segment of the catheter placed distal to the thrombosed aneurysm. During thrombolytic therapy, the patient remained

under close clinical and biological surveillance at the vascular unit. A second round of angiography was performed 24 hours after the start of *in situ* thrombolysis, showing revascularization of the right lower limb with a patent fibular artery distal to the popliteal aneurysm (Figure 2).

A subsequent operation involved excision of the right leg aneurysm and creation of a saphenous femorodistal bypass. A few weeks later, the aneurysm of the left leg was treated with a similar surgical approach. Three years later, the patient continues to do well.

### DISCUSSION

Surgery for thrombosed popliteal aneurysms can have rather disappointing results, with a high rate of secondary amputation, because the distal arterial runoff is usually also thrombosed or inadequate.

In this case report, *in situ* thrombolysis performed prior to the surgical intervention allowed us to “clean” the arterial runoff and largely facilitated the subsequent surgical procedure. We recommend this approach to be used as a general strategy, except for acute limb ischemia with sensory-motor deficit. ■

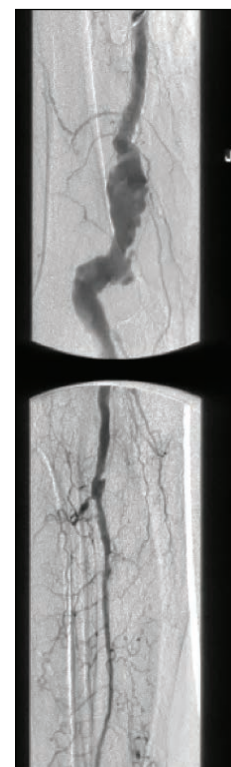
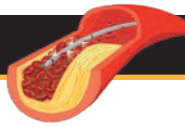


Figure 2. Final angiography after intra-arterial thrombolysis showed a large right popliteal aneurysm and patency of the fibular artery.



## CASE REPORT

## INTRA-ARTERIAL THROMBOLYSIS FOR *IN SITU* THROMBOSIS AND EMBOLIZATION AFTER FEMOROPOPLITEAL STENTING

By Prof. Ludovic Berger, MD, PhD

### DIAGNOSTIC EVALUATION

A 57-year-old man with a history of peripheral occlusive disease was referred to our institution for the treatment of right lower extremity claudication. He had bilateral iliac stenting 8 years before his presentation and bilateral femoral artery recanalization and stenting 1 year prior. Duplex scanning indicated that the claudication recurrence was caused by occlusive evolution of the proximal femoral artery and 6-cm-long in-stent hyperplasia.

### TREATMENT APPROACH

We decided to manage these lesions endovascularly with access via a left femoral artery sheath and crossover to access the right-side arteries. Initial arteriography via a 45-cm, 6-F sheath positioned in the right common femoral artery confirmed the duplex scan diagnosis. It showed a tight stenosis just below the origin of the femoral artery, proximal and distal in-stent hyperplasia, and nonocclusive mural thrombi into the first part of the popliteal artery (Figure 1). After placing two additional long nitinol stents (6- X 120-mm at the origin of the artery and 6- X 150-mm below the first stent), the femoropopliteal axis was redilated. Control arteriography after the procedure showed that, although the proximal part of the femoral artery was patent, the femoropopliteal axis was thrombosed. More importantly, there was distal embolization in all the below-the-knee (BTK) arteries (Figure 2).

To dissolve the thrombus and emboli, a 5-F straight multipurpose catheter was positioned in the popliteal artery. Urokinase was infused at 1,000 IU/kg per hour, while intra-arterial heparin was concomitantly infused through the introducer sheath at 250 IU/kg per 24 hours. Hematocrit, activated thromboplastin time, and fibrinogen level were measured 4 hours after the start of the thrombolytic treatment. At that moment, the patient had clinically recovered, and the distal part of the tibial artery displayed a normal flow (ankle-brachial index, 1). An angiogram was obtained 6 hours after the initiation of thrombolysis, showing complete resolution of the thrombus and emboli with two patent BTK arteries and a patent plantar arch (Figure 3).

The patient was discharged the same day without hemorrhagic complications or any other adverse events.

### DISCUSSION

There are several cases of thrombotic intraprocedural complications that can be challenging to manage. In these instances, an intra-arterial thrombolytic infusion might be an attractive solution. This clinical case illustrates the successful utilization of intra-arterial thrombolytic therapy for the treatment of intraprocedural *in situ* thrombosis and distal embolization, with a recovery of the femoropopliteal axis and outflow. ■

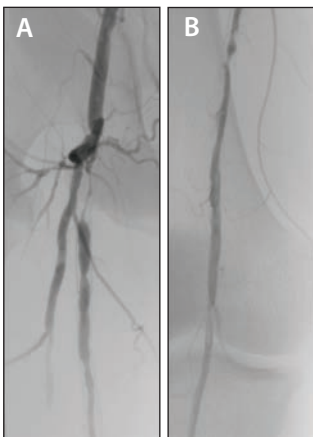


Figure 1. Initial angiogram showed preocclusive stenosis of the proximal part of the right femoral artery and in-stent femoropopliteal restenosis caused by hyperplasia.

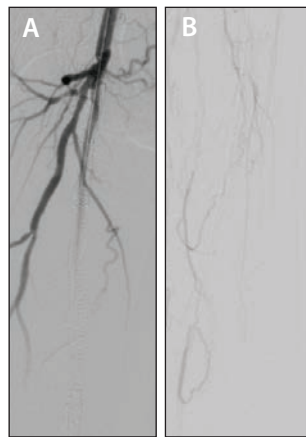

Figure 2. After stenting and remodeling, control arteriography showed thrombosis of the femoropopliteal axis and distal embolization in the BTK arteries.

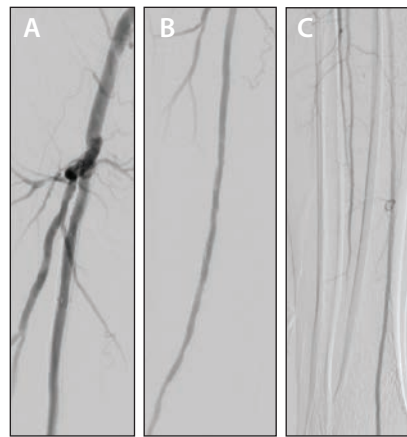
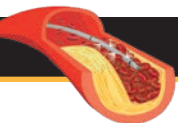


Figure 3. Final angiogram obtained 6 hours after intra-arterial thrombolysis showed full recovery of the femoropopliteal axis and two BTK patent arteries, including the distal part of the tibial artery.





## THROMBOLYSIS AS ADJUNCT THERAPY TO ANGIOPLASTY AND STENTING FOR CRITICAL LIMB ISCHEMIA

By Prof. Eric Ducasse, MD, PhD

### DIAGNOSTIC EVALUATION

An 89-year-old woman presented to our institution with critical limb ischemia involving rest pain and necrosis of the first toe. She was scheduled for angiography and endovascular treatment.

### TREATMENT APPROACH

The patient was brought to the operating room and treated under local anesthesia and sedation. A direct puncture was made at the proximal part of the superficial femoral artery (SFA) with a 4-F, 13-cm access sheath (Terumo), and initial angiography was performed.

The initial angiogram showed an occlusion of the distal part of the SFA and the entire popliteal artery, and blood flow resumed in the mid-peroneal artery (Figure 1). Direct recanalization was performed with an 0.018-inch V-18 guidewire (Boston Scientific Corporation) inserted down to the peroneal artery. An initial predilatation was performed with a 2.5- X 8-cm balloon for 1 minute.

Next, the tibioperoneal trunk and the distal part of the popliteal artery were treated with a 3-mm X 4-cm balloon for 1 minute; the mid and proximal parts of the popliteal artery and the distal part of the SFA were treated using a 4-mm X 8-cm balloon.

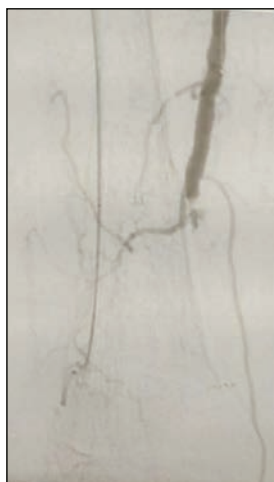


Figure 1. The initial angiogram showed an occlusion at the distal third of the SFA, involving the whole popliteal artery and tibioperoneal trunk on the right side.

Control angiography showed a flow-limiting dissection affecting the entire popliteal artery. A long, self-expanding, 5-mm X 8-cm Pulsar-18 nitinol stent (Biotronik) was used to scaffold the reopened artery. After popliteal stenting and a long inflation, the reopened popliteal artery wall showed remaining thrombus extending down to the peroneal artery (Figure 2).

The decision was made to deliver a 600,000-IU bolus of urokinase to induce the destruction of the remaining blood clots and increase the global outflow. After thrombolytic injection for 30 seconds and inflation with 3-mm X 4-cm and 4-mm X



Figure 2. After stenting of the P1 and P2 segment of the popliteal artery, angiography showed remaining thrombotic clots along the wall of the reopened artery down to the peroneal artery.

4-cm balloons for 3 minutes each, final control angiography showed good results with satisfactory blood flow and direct connection to the remaining peroneal artery (Figure 3).

### DISCUSSION

Adjunct treatment with thrombolysis is frequently used in our current practice for endovascular treatment of below-the-knee arteries. This adjunct therapy may increase the outflow by removing any residual thrombus or microemboli in the small distal or collateral arteries, and subsequently enhance procedural results and clinical follow-up. ■


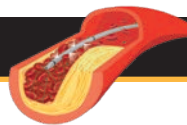


Figure 3. After a bolus of thrombolytic agent and angioplasty, the final angiogram showed the improved reopened artery below the stent.



## ENDOVASCULAR TREATMENT OF AN ACUTE OCCLUSION OF A RENAL ARTERY

By Prof. Hervé Rousseau, MD, PhD

### DIAGNOSTIC EVALUATION

A 55-year-old woman with no particular medical history apart from long-standing arterial hypertension presented to our hospital. Violent lumbar pain led to a CT scan, showing fibromuscular dysplasia lesions in both renal arteries, a non-obstructive dissection on the left side, preocclusive lesions on the right side, and bilateral renal infarction (Figure 1). After a multidisciplinary consultation, the decision was made to revascularize the right renal artery, with the purpose of preserving renal function.

### TREATMENT APPROACH

Initial angiography showed extensive fibromuscular dysplasia lesions in both renal arteries, with extension to the intrarenal branches on the right side (Figure 2A). Angioplasty was performed, but immediate control showed residual stenosis and a dissection in the arterial trunk (Figure 2B). Subsequently, two 6- X 18-mm stents were placed with good angiographic results (Figure 2C). The patient returned home after 2 days under antiaggregant treatment.

The patient presented with extreme pain in the right lumbar fossa 5 days after the angioplasty. A CT scan was performed, showing stent thrombosis and almost

complete right renal ischemia. The same day, *in situ* thrombolysis was started (Figure 3).

Arteriography before thrombolysis showed obstruction of the right renal arterial trunk, and after catheterization of this occlusion, only one branch of the intrarenal division was permeable (Figure 4A). After withdrawing the catheter until the ostium of the right renal artery, a 100,000-IU bolus of urokinase was administered, followed by an infusion of 4,000 IU/min urokinase for 4 hours and a subsequent infusion of 1,000 IU/min urokinase for 10 hours with parallel heparin infusion via a long 5-F introducer sheath. Angiographic control at 12 hours showed the permeabilization of all arteries (Figure 4B). The presence of residual stenosis at the ostium of the right renal artery required the placement of another proximal prosthesis.

The postintervention course was simple, with renal function restoration and disappearance of pain. The patient was kept on low-molecular-weight heparin for 3 days, followed by low-dose acetylsalicylic acid and clopidogrel for 2 months.

### DISCUSSION

Percutaneous revascularization has proven to be a safe and effective procedure in the treatment of total renal artery occlusion. The indications and technique of local

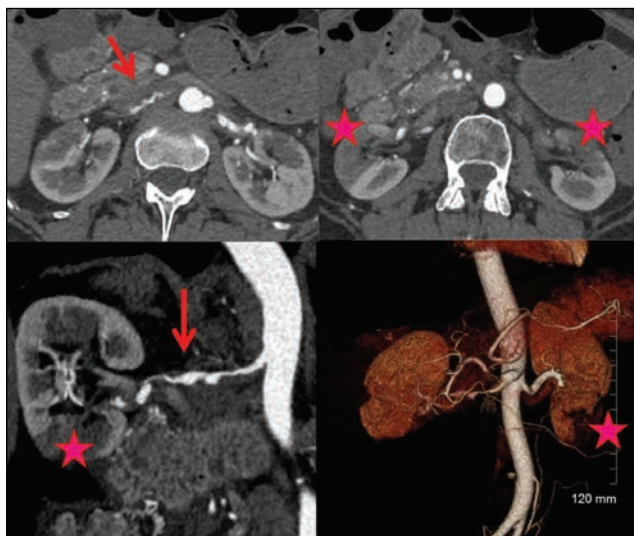


Figure 1. Presence of bilateral fibromuscular dysplastic lesions in the renal arteries with a dissection at the left side, an irregular stenosis at the right side (arrow), and the presence of segmental infarction in both kidneys (star).

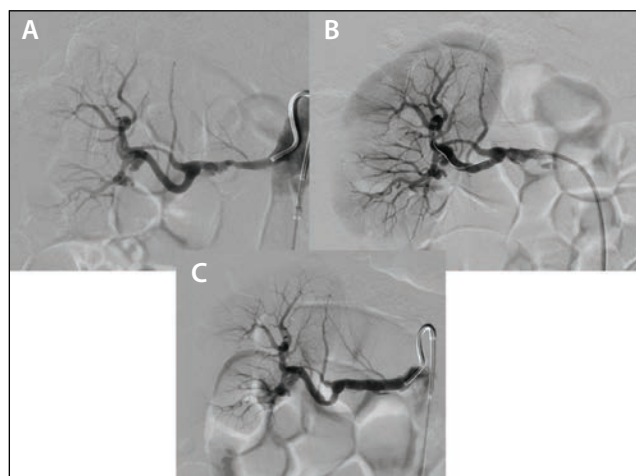

Figure 2. Presence of a preocclusive stenosis of the terminal part of the right renal arterial trunk in combination with distal intrarenal lesions (A). Results after angioplasty, with residual stenosis and a local dissection (B). Placement of two stents, resulting in recovery of a normal diameter (C).

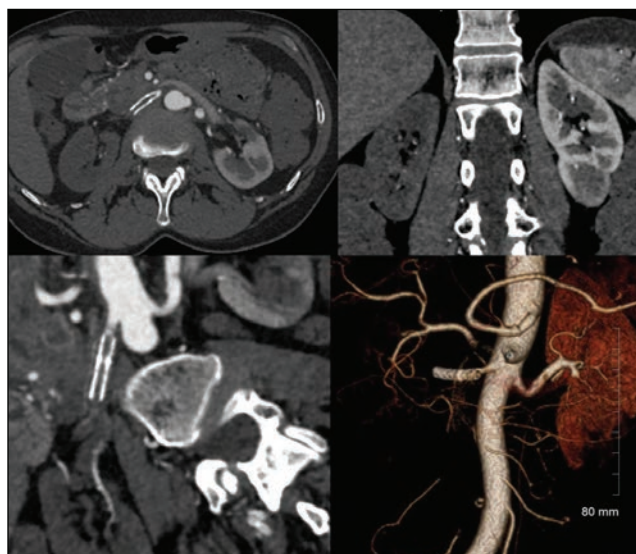
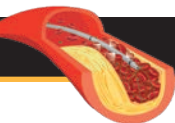


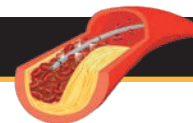
Figure 3. Conventional CT scan with three-dimensional reconstructions. Presence of an occlusion of the stent in the right kidney and right renal ischemia.

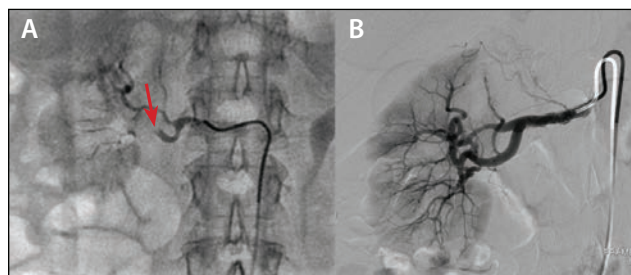

Figure 4. Distal angiography after catheterization of the stent occlusion. Vascular amputation of the retropericeliac branch (arrow) with a floating thrombus (A). Repermeabilization of the arteries after 12 hours of thrombolytic treatment (B).

thrombolysis therapy for acute renal artery occlusions are discussed in this case report. The result of treatment depends largely on the time interval between occlusion and the beginning of treatment, but thrombolysis seems to be an effective treatment that may save renal function after up to 24 hours of arterial occlusion. ■





## CASE REPORT

## ENDOVASCULAR REVASCULARIZATION OF A RENAL BRANCH ACUTE OCCLUSION IN A THREE-BRANCHED STENT GRAFT

By Prof. Hicham Kobeiter, MD, PhD, and Dr. Vania Tacher, MD, PhD

### DIAGNOSTIC EVALUATION

A 64-year-old woman was treated with a branched stent graft (the three branches were positioned into the celiac trunk, the superior mesenteric artery, and the left renal artery) for a thoracoabdominal aneurysm. Three months later, she went into acute renal failure due to an acute left renal branch thrombosis diagnosed with duplex ultrasound.

### TREATMENT APPROACH

After intravenous heparin injection, angiography was performed under local anesthesia with a humeral approach. Left renal thrombosis was found via digital subtraction angiography (DSA) (Figure 1). The catheter and guidewire were introduced into the left renal branch and arterial trunk. DSA revealed a fracture of the distal renal branch stent, which was assumed to be the cause of the thrombosis. First, an intrastent dilatation with a 6- X 40-mm balloon was performed to straighten the stent axis. A 6- X 24-mm and a 6- X 16-mm balloon-expandable stent were successfully

placed into the fractured stent for alignment. No flow was initially found in the stents, the renal artery, or the renal parenchyma after stent placement.

The flow was completely and immediately recovered in the branch, the stents, the left renal artery, and the renal parenchyma after *in situ* thrombolysis with a single 100,000-IU bolus of urokinase administered per intervention through a catheter (Figure 2).

Control DSA of all three branches of the endograft confirmed their patency. The patient regained renal function, with moderate renal failure. At follow-up, all three branches remained patent, and the patient did not require dialysis.

### DISCUSSION

In this case, successful left renal branch revascularization of a branched endograft was achieved using a thrombolytic agent to resolve the acute thrombosis and stent placement to treat the cause and avoid recurrence. ■

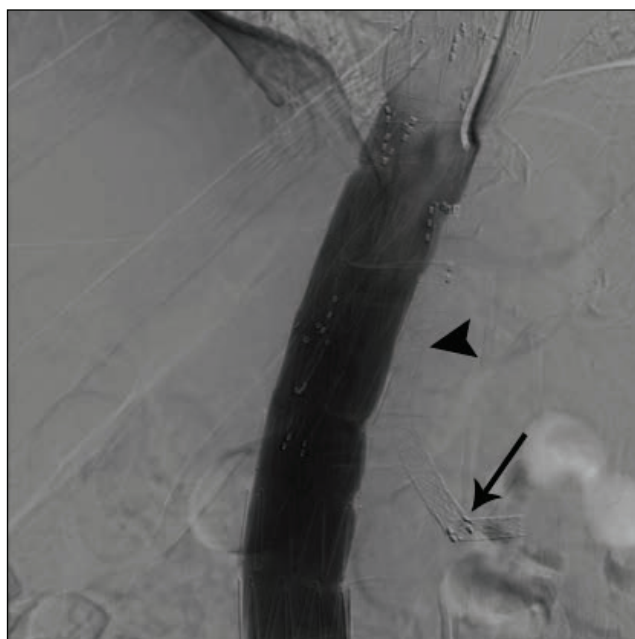


Figure 1. Initial aortography of the left renal branch level showed a complete occlusion of the left renal branch (arrowhead) and the stents with no nephrogram. The distal stent was fractured (arrow).

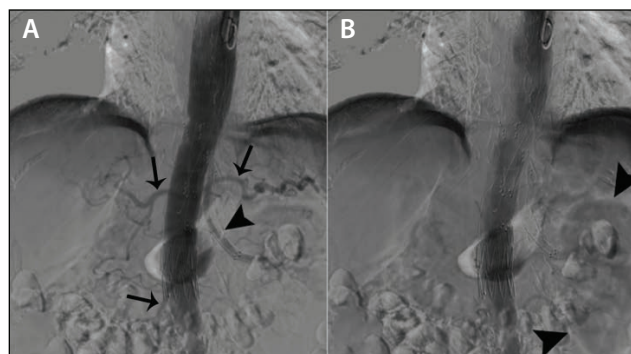


Figure 2. At the end of the intervention, final aortography showed the patency of all three branches: the celiac trunk and its branches (arrows), the superior mesenteric artery (arrows), and the left renal artery (arrowhead) (A). It also showed the apparition of a left nephrogram (arrowheads) (B).